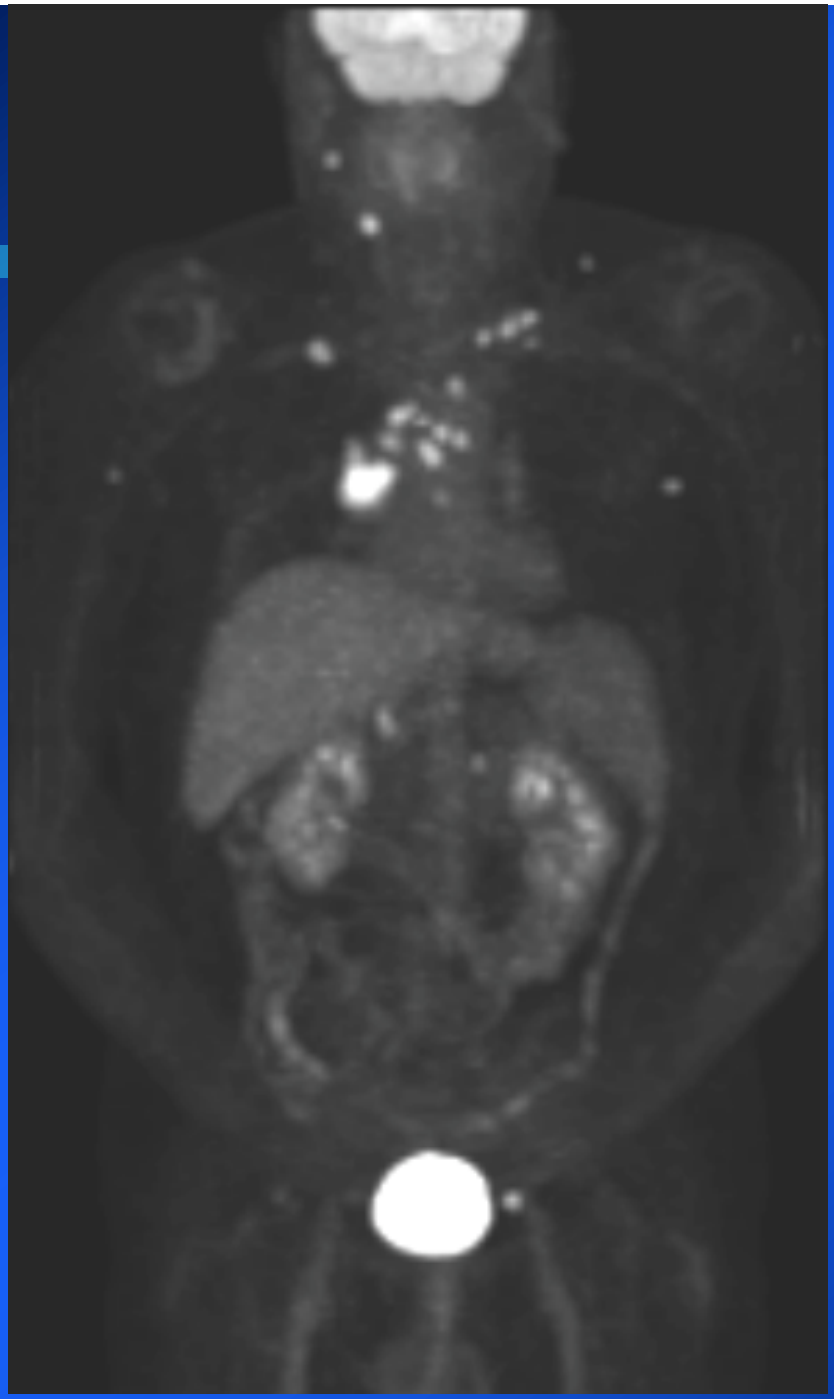

Translational Molecular Imaging

Val J. Lowe, MD
PET Facility
Mayo Clinic

What is Molecular Imaging?

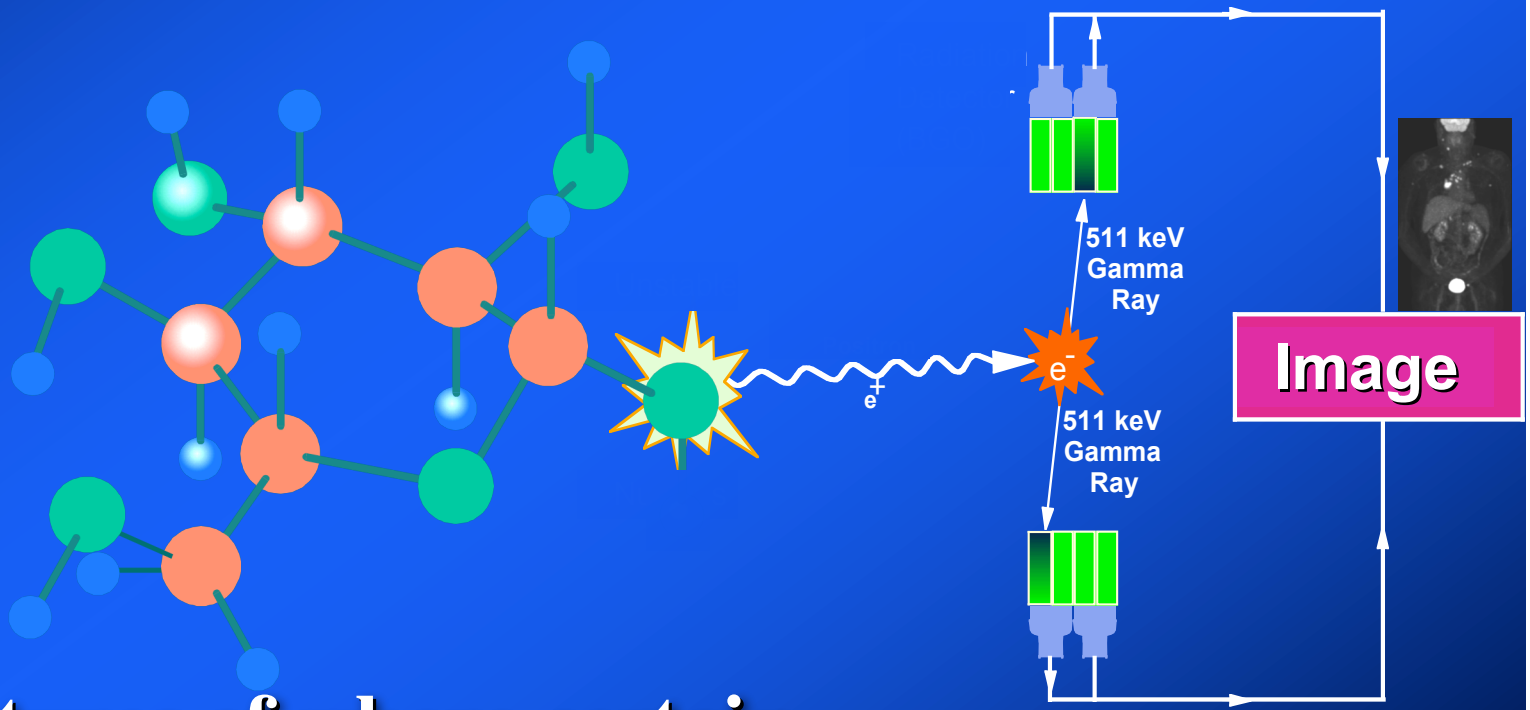

Pictures of where certain molecules are and how they are functioning in a living organism.

Lowe,VJ

Translational Molecular Imaging

Goals

1. Image oncologic cellular characteristics; metabolism, proliferation, angiogenesis, apoptosis, etc.

2. Use for clinical cancer detection

3. Use for clinical physiologic measurement of cancer; prognosis, treatment selection (molecular therapy), therapy response assessment.

Translational Molecular Imaging

Research Aims

1. Develop markers of different cellular functions.
2. Test imaging of markers in preclinical models.
3. Translate to human trials

Translational Molecular Imaging

Tools

1. Molecular Medicine/Cellular Biology
2. Synthetic Organic Chemistry
3. Radiochemistry
4. Imaging Science

Radioisotope production

Lowe,VJ

Translational Molecular Imaging

Cellular Metabolism Imaging:

F-18 Fluorodeoxyglucose PET

Lowe,VJ

F-18 FDG

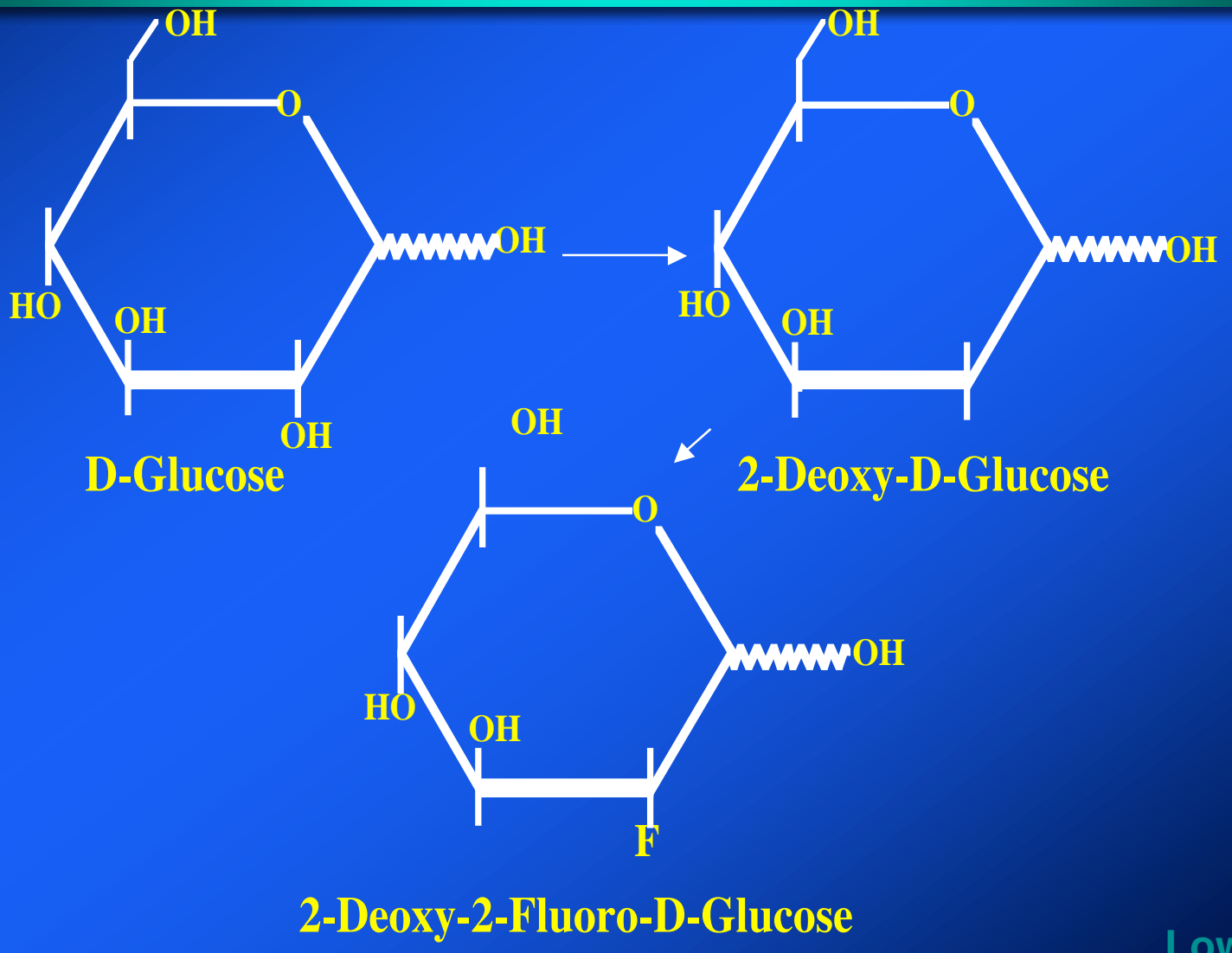

Lowe,VJ

Pt: EH

Htx: L lung mass found in workup for back pain.

Imaging: CT, L lung mass, else negative; bone scan negative, rib and spine films negative

Htx: L lung mass found; workup for back pain.
Imaging: CT, L lung mass, else negative; bone scan negative, rib and spine films negative

PET: Lung CA, multiple metastasis

Much more disease than detected previously
Expired one month later

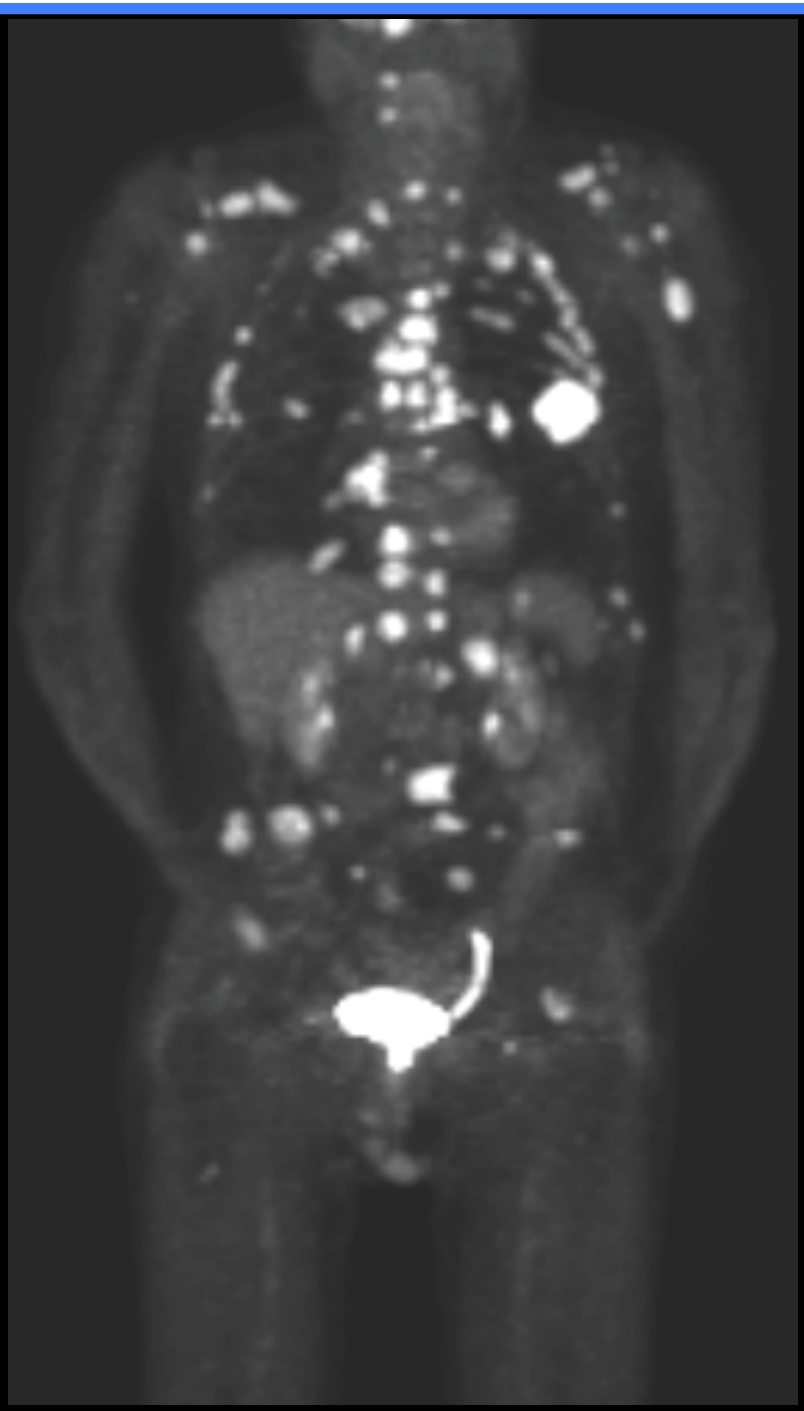

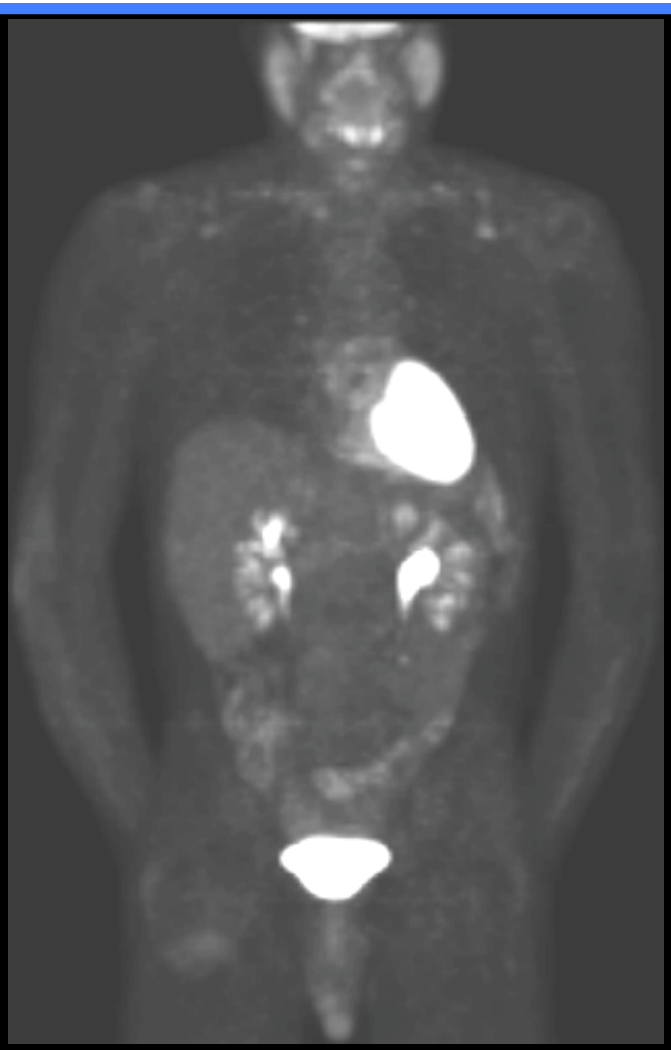

Pretrx **Posttrx**

Pt:RE Htx: NHL, post treatment Y2B8

CT: Minimal interval improvement in lymph nodes

PET: Marked improvement

Much more accurate disease assessment by molecular imaging

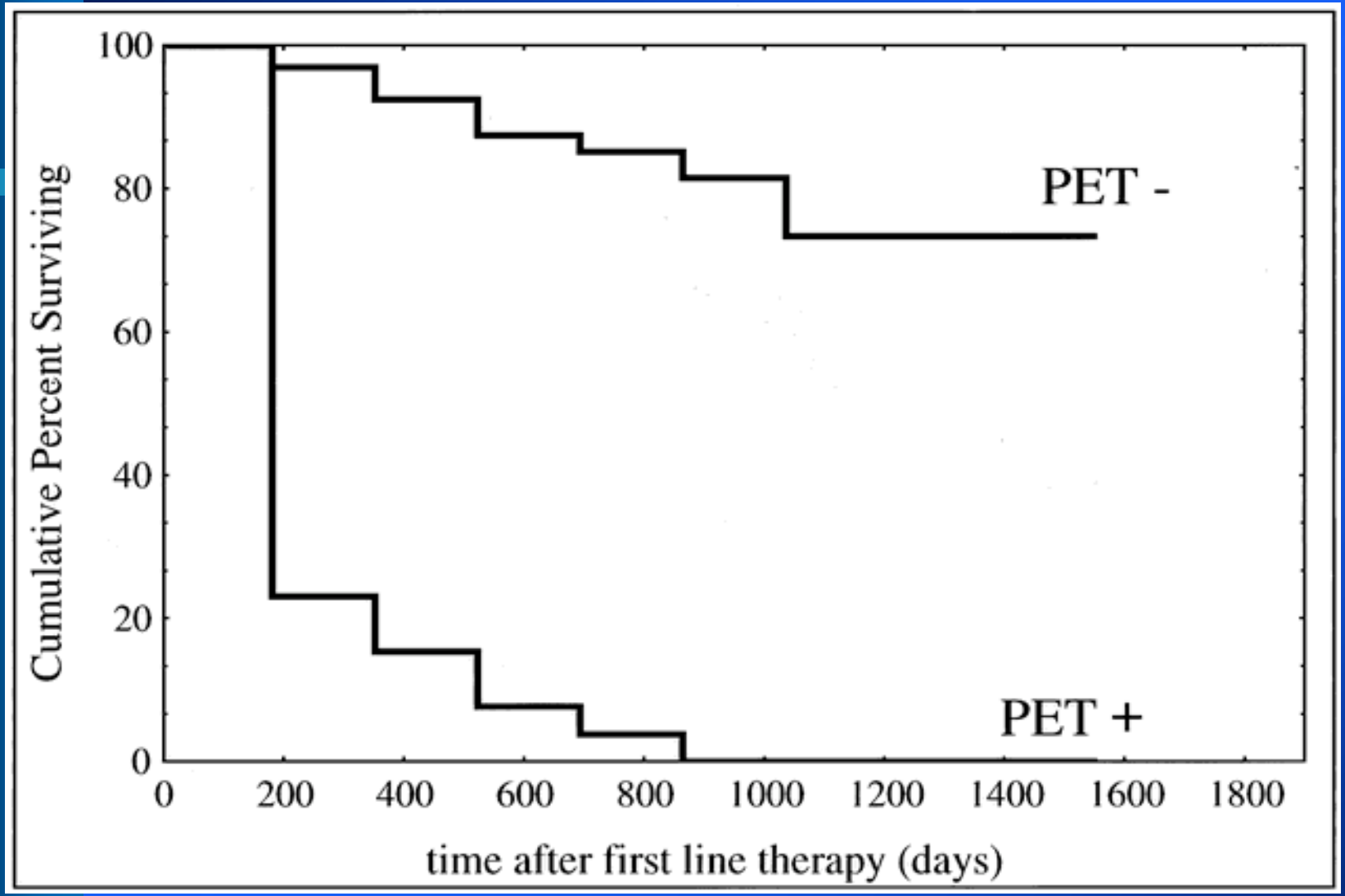

Fig 4. Kaplan-Meier estimate of PFS in 26 patients with a positive [18F]FDG-PET after therapy compared with 67 patients with a negative [18F]FDG-PET after therapy.

Spaepen: JCO, Volume 19(2).January 15, 2001.414-419 Lowe,VJ

Therapy Assessment

Molecular Therapy Assessment

GIST response to Gleevic can be seen as soon as 24 hours after initiation of therapy with FDG PET

Such rapid response assessment is not likely with anatomic imaging to detect size changes.

Lowe,VJ

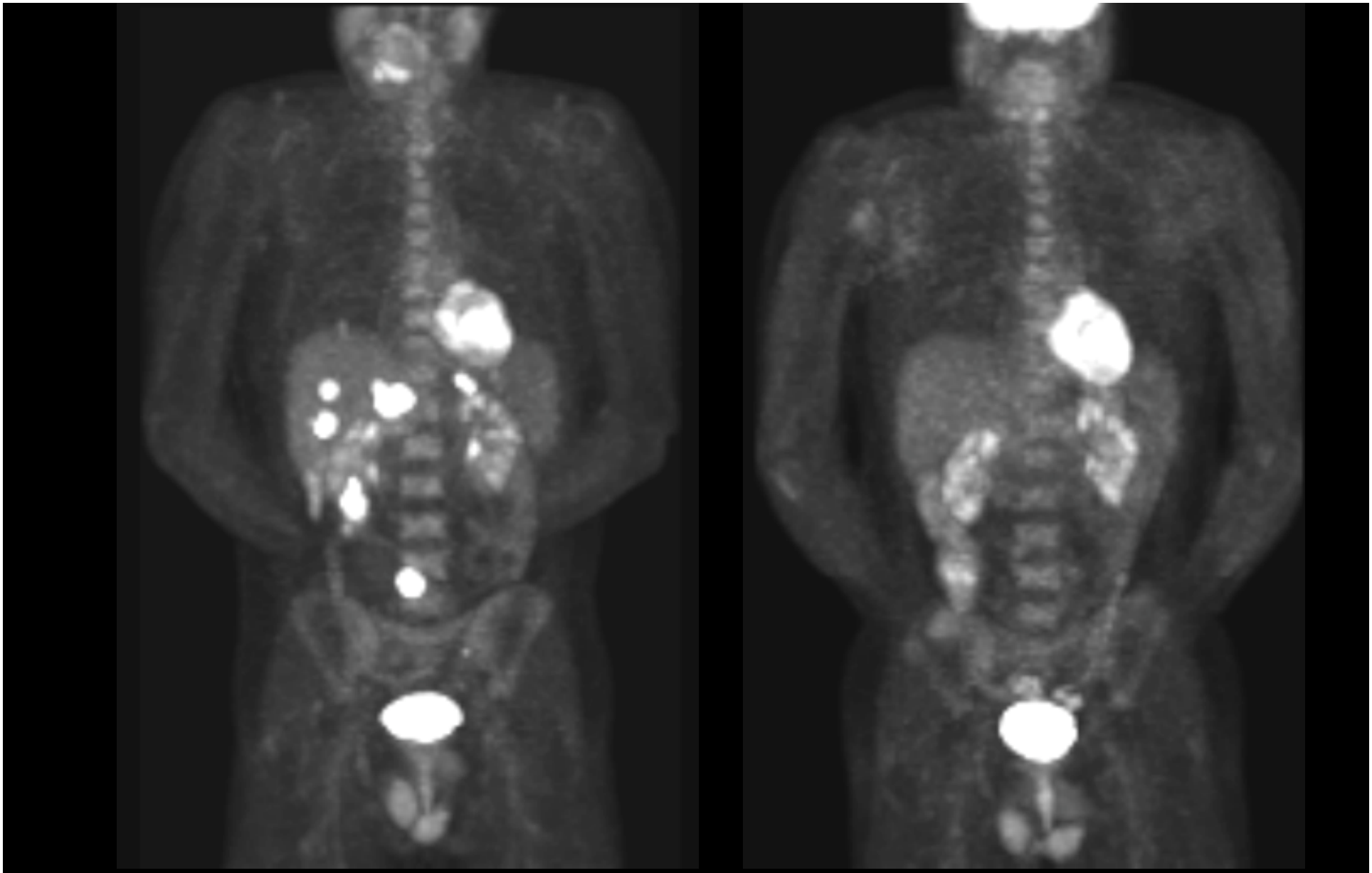

PET: Shows a complete response.
Before and after 5 days of Gleevic therapy.

Translational Molecular Imaging

Cell Membrane synthesis Imaging:

C-11 Choline/ Acetate PET; MRI

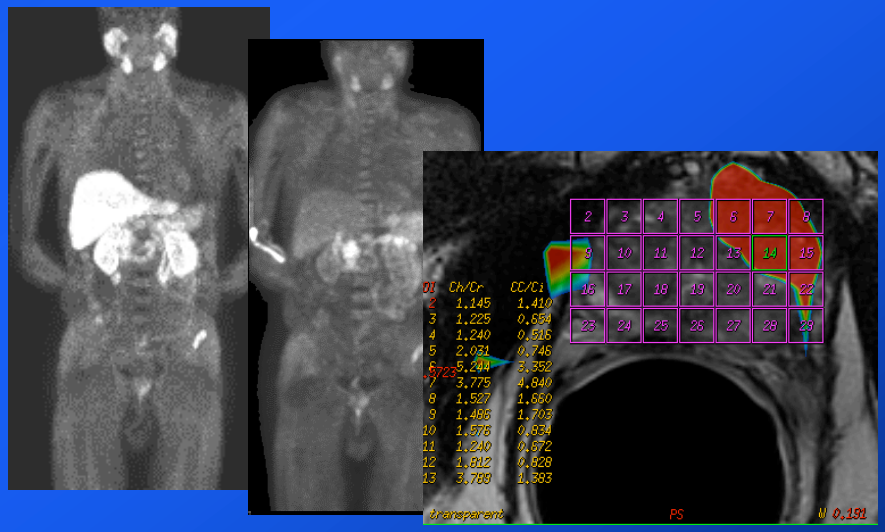

Lowe,VJ

[^{11}C]choline

Prostate cancer, like other malignancies, is commonly characterized by increased uptake of choline.

Choline is used for increased synthesis of phosphatidylcholine, an important cell membrane phospholipid.

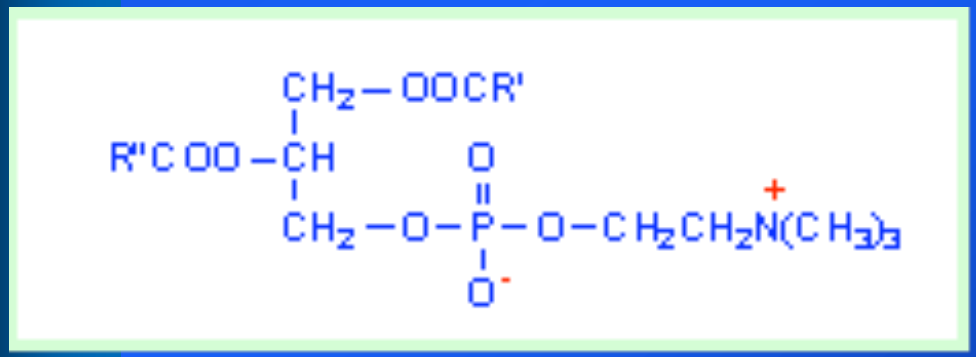

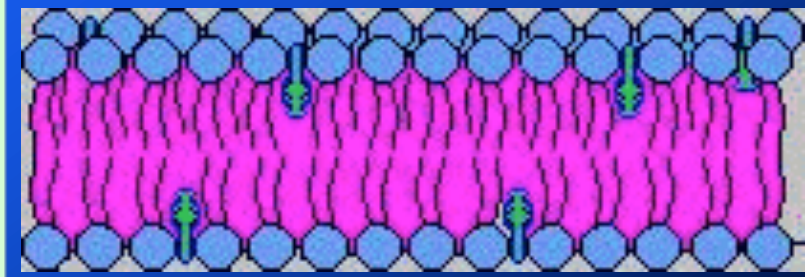

phosphatidylcholine cell membrane lipid bi-layer

Lowe,VJ

[^{11}C]choline

- Male athymic nude mice
- LnCAP cells

Lowe,VJ

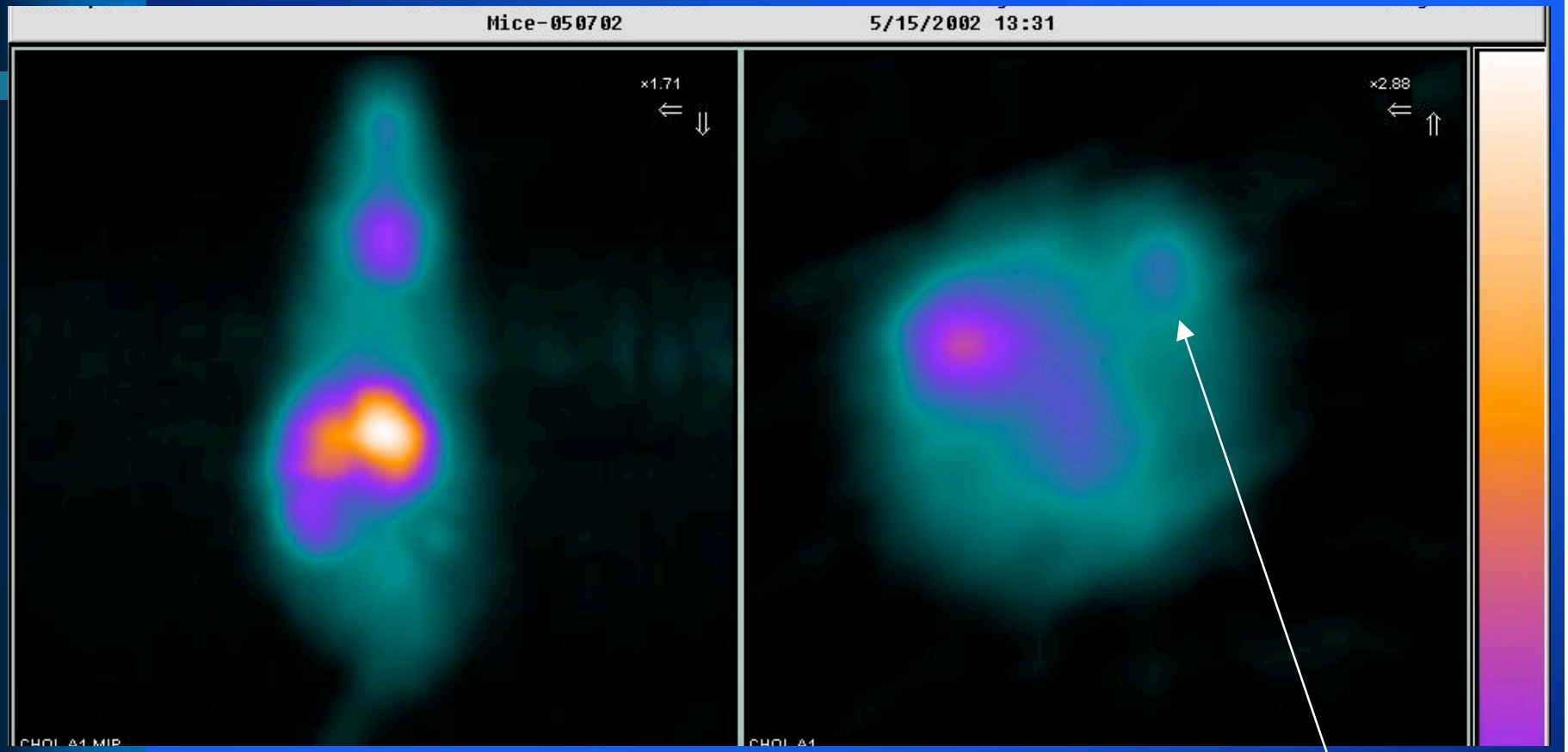

Choline: 6% uptake

Lowe,VJ

Patient #1

C11 Choline

C11 Acetate

Lowe,VJ

Patient #1

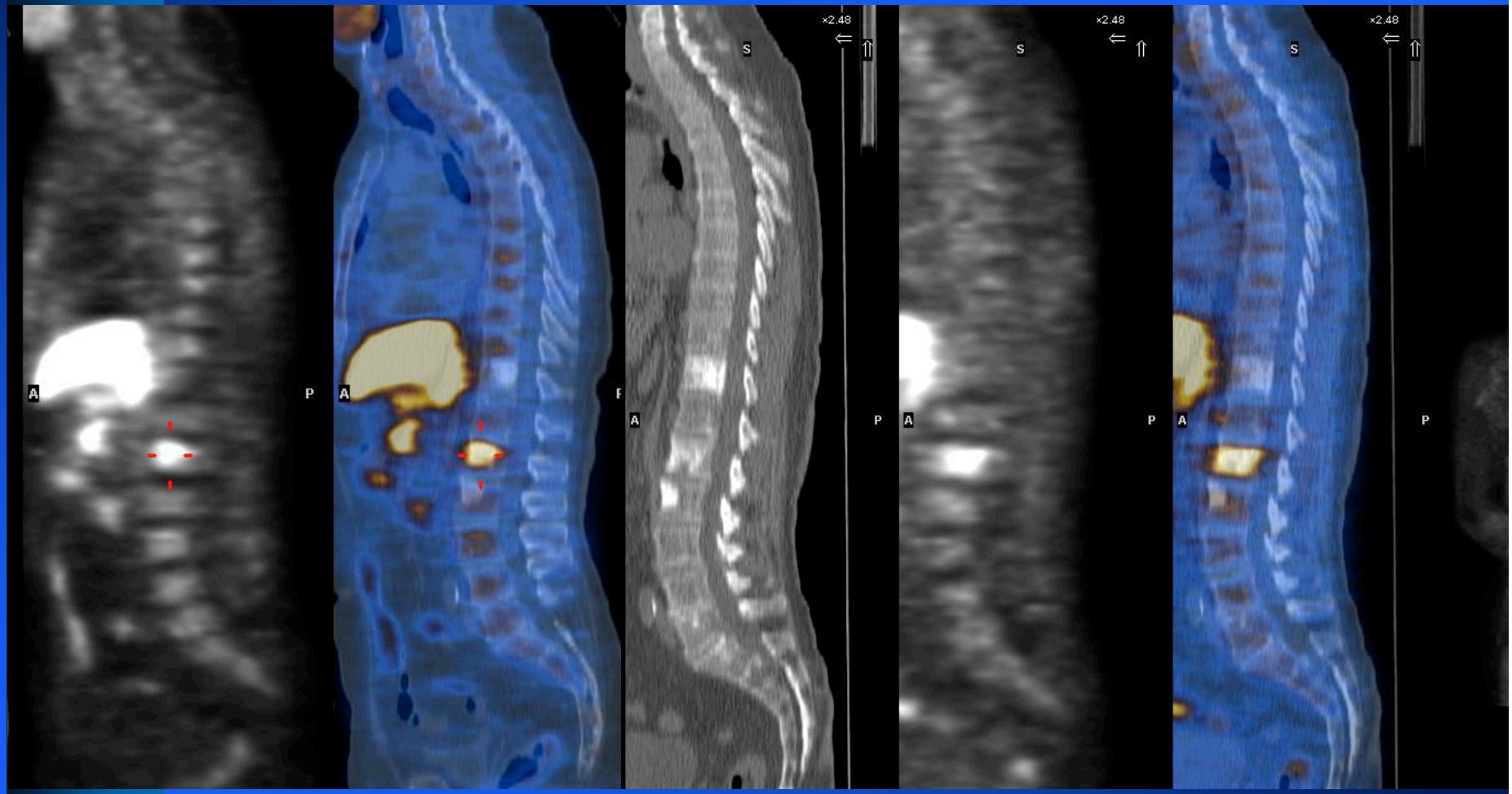

C11 Choline

C11 Acetate

Lowe,VJ

GE MEDICAL SYSTEMS
SIGNA EXCITE RMNSOW
Ex 8728/5040678-1
Se: 3
Im: 4
Sag Sag L5.3(coi)
S 149
MAYO CLINIC MRI NS
M71Y/Aug 29 1932
Apr 13 2004
12:42:27 PM
Mag = 1.38
FL:
ROT:
Lesion #1
Lesion #2
Lesions #3
ET:6
A
9
5
P
I
5
9
NONE
TR:650 SE
TE:8.1/Ef
EC:1/1 41.7kHz
5GP
FOV:
5.0thk/0.0sp/C
/00:18
320X192/1.00 NEX
FC_FREQ_AX\FC\SAT\VB\TRF\SP
I 105
WW: 442WL: 124
GE MEDICAL SYSTEMS
SIGNA EXCITE RMNSOW
Ex 8728/5040678-1
Se: 4
Im: 1
Ax Ax S86.2(coi)
M71Y/Aug 29 1932
Apr 13 2004
12:44:57 PM
Mag = 1.00
FL:
ROT:
Lesion #1
ET:6
R
I
5
2
L
I
4
8
NONE
TR:650 SE
TE:7.6/Ef
EC:1/1 41.7kHz
5GP
FOV:
6.0thk/1.0sp
/00:39
320X192/1.00 NEX
FC_SLICE_AX\FC\SAT\VB\TRF\SP
P 135
WW: 516WL: 188

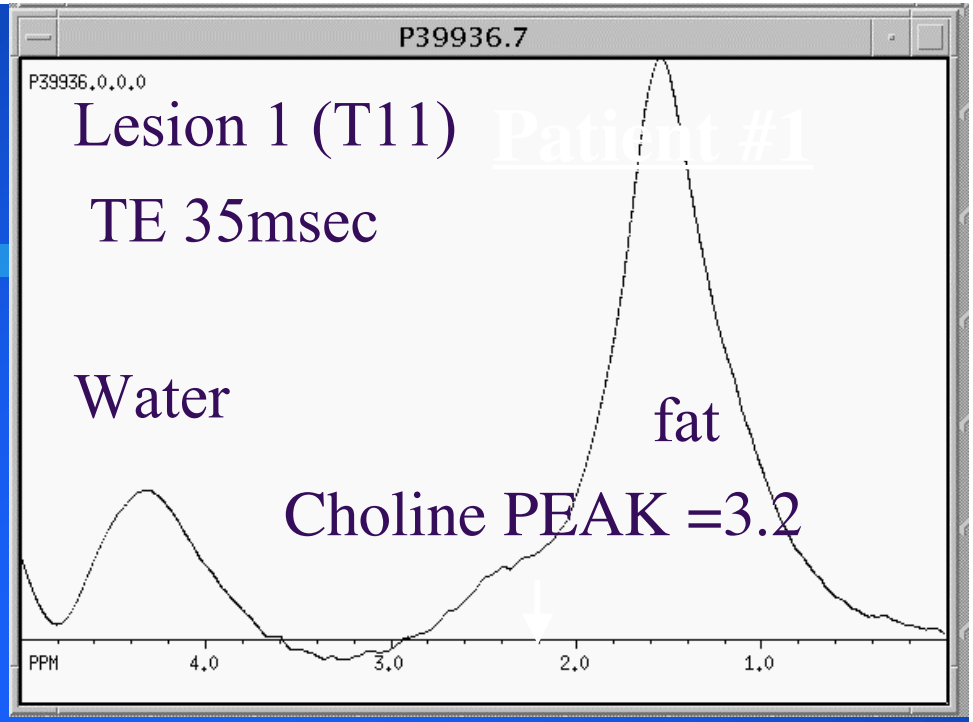
P39936.7
P39936.0.0.0
Lesion 1 (T11)
Patient #1
TE 35msec
Water
fat
Choline PEAK =3.2
PPM
4.0
3.0
2.0
1.0

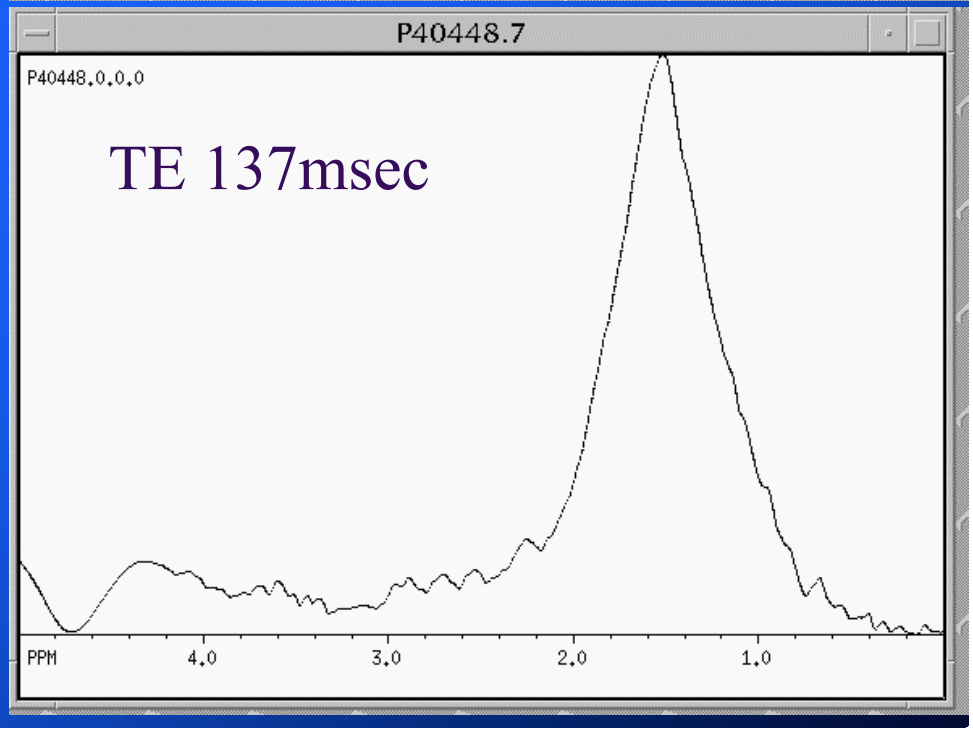
P40448.7
P40448.0.0.0
TE 137msec
PPM
4.0
3.0
2.0
1.0

Translational Molecular Imaging

Gene Expression Imaging:

Virus Transfection mapping

Sodium Iodine Symporter (NIS) using I-124 PET or I-123, I-131 SPECT

Combined ^{124}I PET/CT imaging of NIS gene therapy in animal models; Cancer can be treated if it "lights up" on the scan.

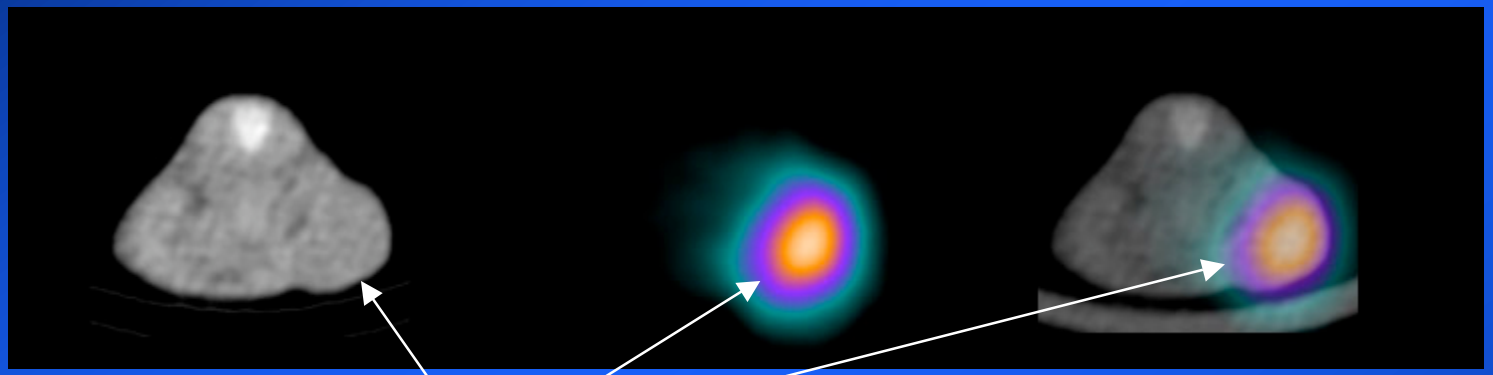

Multiple myeloma expressing NIS

Normal Bladder

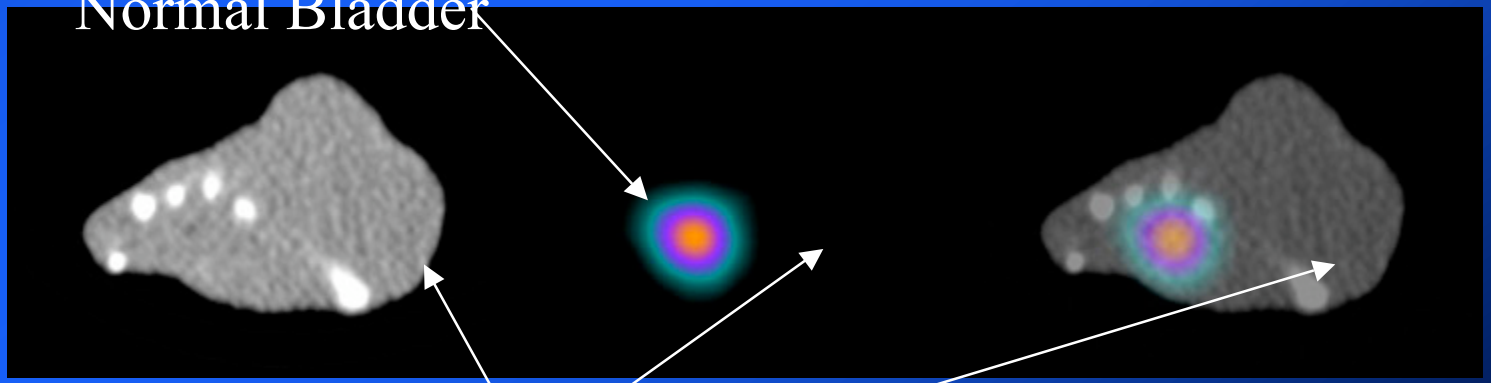

Multiple myeloma not expressing NIS

Lowe,VJ

Translational Molecular Imaging

Cellular Proliferation Imaging:

F-18 Fluorothymidine PET

Lowe,VJ

Evaluation of EGFR inhibitor therapy by FLT PET/CT imaging:

Imaging of this tumor can be done before and after drug treatment to monitor effects on cancer proliferation.

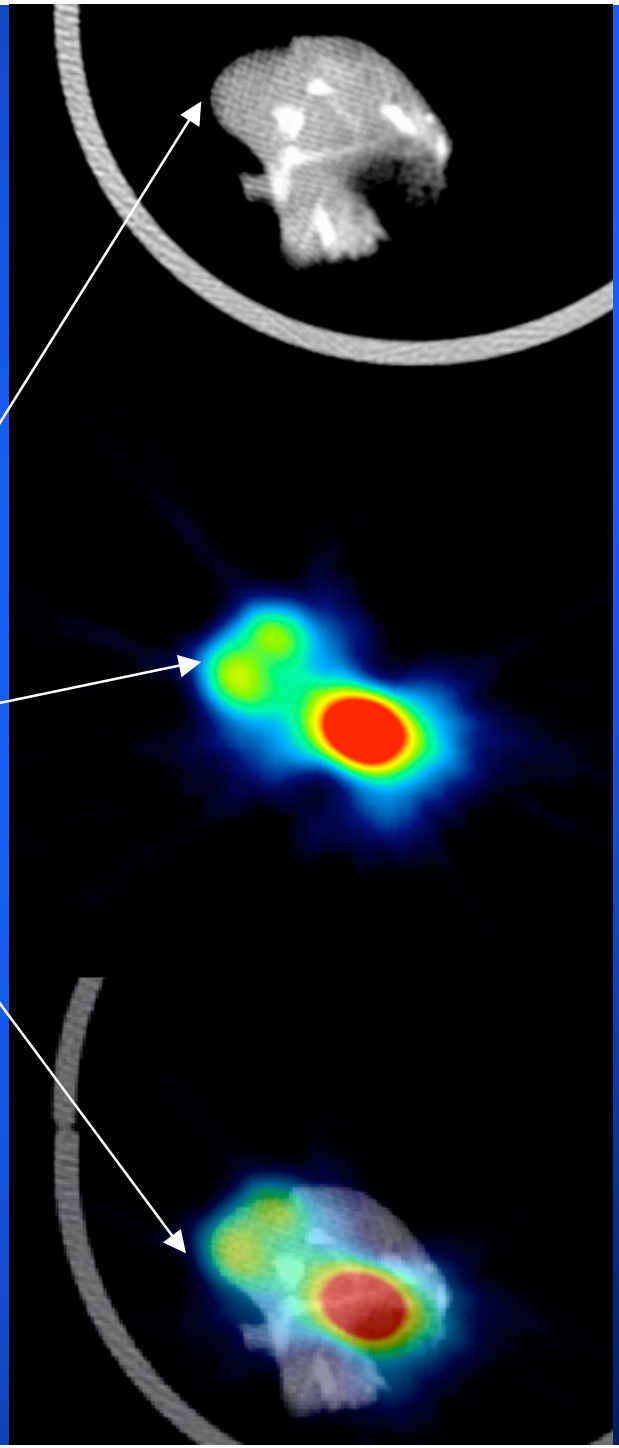

Lowe,VJ

Translational Molecular Imaging

Summary

1. Collaboration is essential from many disciplines
2. Clinical cancer detection can be improved
3. Clinical selection and testing of novel therapies in a rapid manner is possible and has significant potential to greatly impact patient management.

The End
Lowe,VJ